

A Case Report: Treatment Risk-Benefit in a Case of PTSD Psychosis

Initial Presentation

62yo female with PMH of alcohol use disorder & bipolar disorder 1 with psychosis presented to the ED with visual/auditory hallucinations, abdominal pain, chest pain, self induced vomiting, and labs significant for ketoacidosis. Admitted to medicine.

- “I see Satan and he’s poisoning me! I need to get the poison out!”

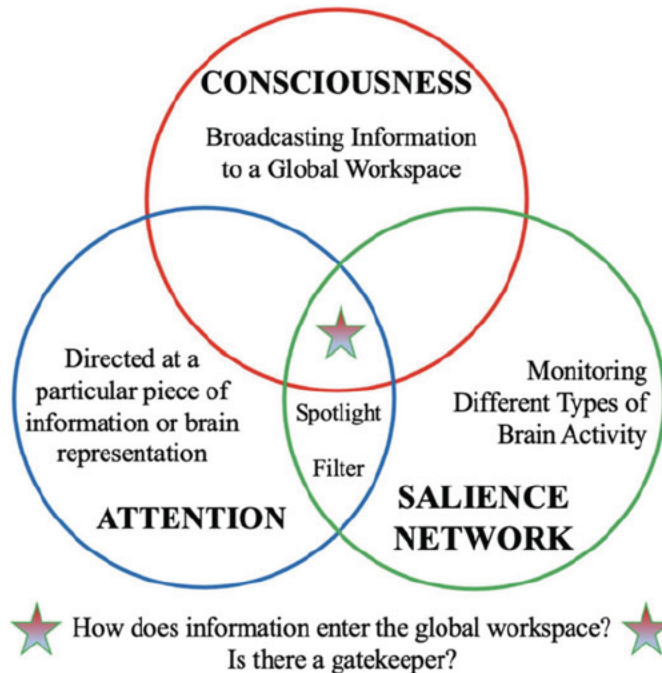


Figure 1: Functional network model of sensory hallucinations. (Hare, S. M. [2021]. *Hallucinations: A functional network model of how sensory representations become selected for conscious awareness in schizophrenia*. *Frontiers in Neuroscience*, 15. <https://doi.org/10.3389/fnins.2021.733038>)

Hospital Course

- Psych consulted first.
- Recent discharge from inpatient psych.
- Poor compliance with Bupropion, Olanzapine, Risperidone.
- Visual/auditory hallucinations of “Satan” or little devils.
- Trauma history (abuse by past partner).
- Questionable mania history.
- Cross-tapered from olanzapine to risperidone.
- Refractory visual hallucinations, ego-dystonic.
- Neurology consulted second for possible Lewy Body Dementia.
- Suggestible olfactory hallucinations.
- Restless leg syndrome but no parkinsonism.
- Non-focal neuro exam.
- DDx: BP1 with psychosis vs. Lewy Body Dementia vs. Charles Bonnet Syndrome.

Diagnostic Work-Up

- Brain imaging negative and non-focal Neuro exam.
- EEG normal → less likely to be occipital seizures or toxic/metabolic encephalopathy.
- Exam & history not consistent w/ Lewy Body Dementia or Charles Bonnet Syndrome.
- VH refractory to phenobarbital inconsistent w/ Alcohol Use Disorder.

Assessment/Plan

- Felt to be primarily PTSD.
- Cross-taper off risperidone onto Zoloft + Atarax.
- Hallucinations resolved. Concern of exaggerating symptoms throughout hospitalization for secondary gain (Pt expressed desire for admission to inpatient psych unit).
- Discharged to outpatient therapy and med management follow-up

Discussion

- Risk/Benefit 1: addressing visual hallucinations as psychiatric, not neurologic.
 - Relied on symptom timeline & thorough neurologic exam.
- Risk/Benefit 2: discontinuing antipsychotics & starting SSRI in a patient with active hallucinations and history of bipolar diagnosis.
 - Adequately trialed risperidone before switching and reliance on literature evidence for PTSD with psychosis as emergent diagnosis.
- Risk/Benefit 3: discharging patient with recent hallucinations & PTSD to outpatient care without inpatient psych hospitalization
 - Importance of thorough suicide risk assessment with motivational interviewing.